





# Stories from the UZA cardiogenetics wonderbook

## UZA has become European Reference Center

Prof. Dr. J. Saenen

1



# Angina Pectoris in the young

2

**Angina Pectoris in the young**


**Mark, 60 y.o.**



Ex-smoker  
AHT  
Dyslipidemia

Likes nice food




Angina Pectoris  
Levine's signs

3

**Angina Pectoris in the young**

**Who would **NOT** refer Mark for cardiac investigation ?**

4

 **Angina Pectoris in the young**   
kennis / ervaring / zorg

**Olivia, 19 y.o.**





Blanco history  
No risk factors



Likes to work-out

Angina Pectoris during running

Levine's signs


5

 **Angina Pectoris in the young**   
kennis / ervaring / zorg


 

**Who would refer Olivia for cardiac investigation ?**

6



## Angina Pectoris in the young



### Olivia, 19 y.o.






2018 OHCA


During sport

Bystander CPR


Successful resuscitation

Transfer UZA



7



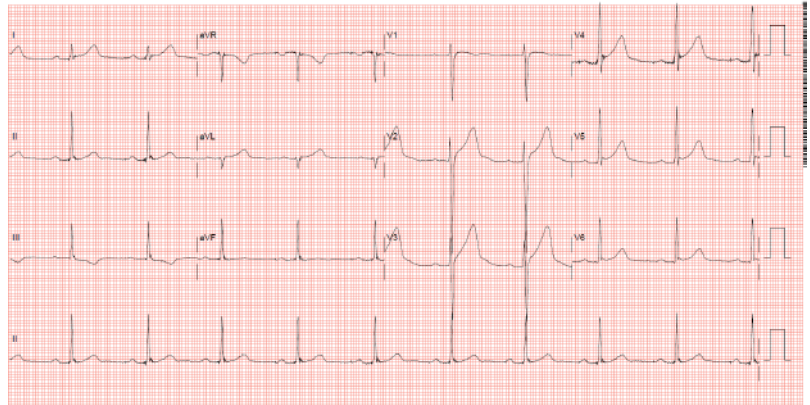
## Angina Pectoris in the young



### Olivia, 19 y.o.

	26/02/2018 04:08	25/02/2018 04:41	24/02/2018 19:15	Eenheid	Laatste Ref. waarden
Troponine I	+ <u>1.35</u>	+ <u>7.11</u>	+ <u>0.056</u>	µg/L	≤ 0.045
CKMB massa	+ <u>25.9</u>	+ <u>22.2</u>		µg/L	≤ 3.6



UZA - INZO - Toestellen P 0.15 - 150 Hz 25 mm/sec 10 mm/mV (15)

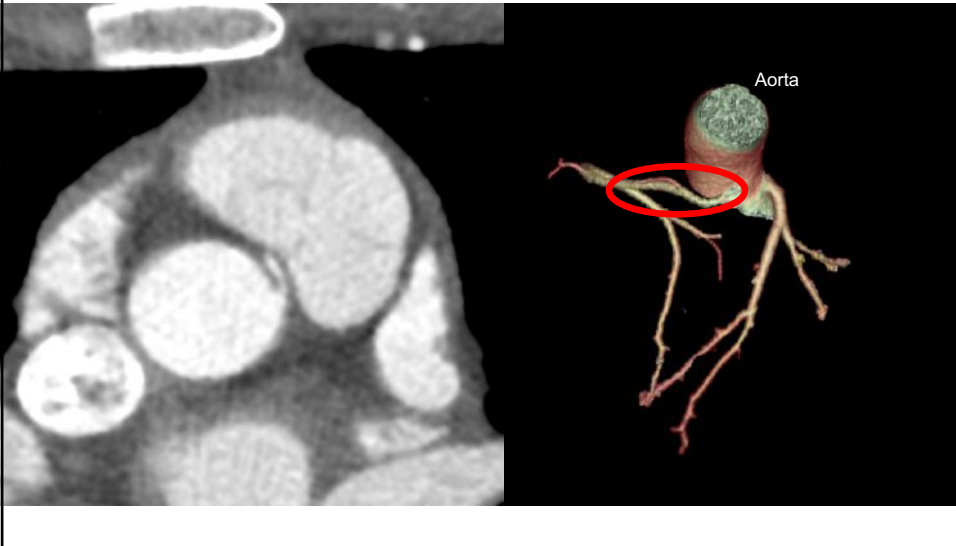
8

**Angina Pectoris in the young** **UZA**  
kennis / ervaring / zorg

**Olivia, 19 y.o.**

**Aberrant RCA origin**

European Reference Network  
for rare or under-recognized complex disorders  
© European Heart League  
2019/2020/2021

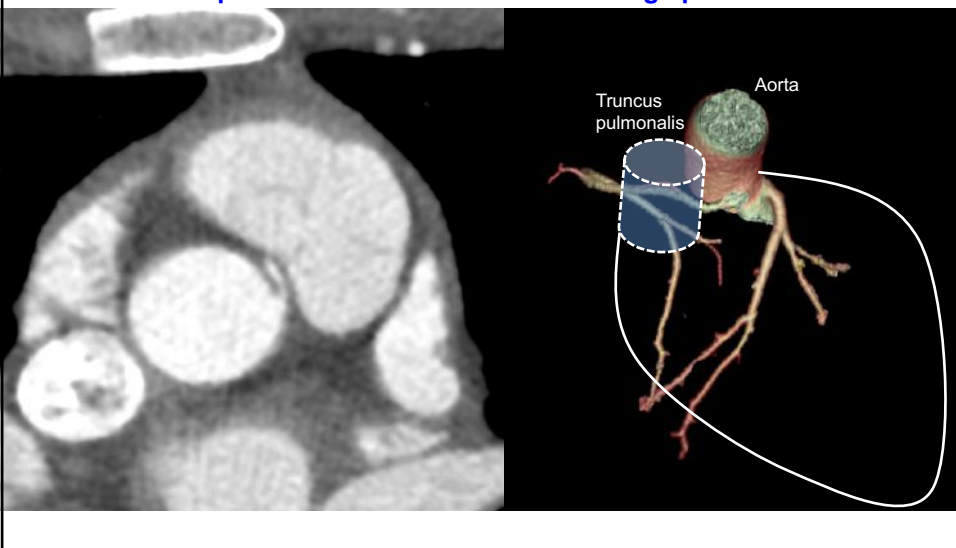


9

**Angina Pectoris in the young** **UZA**  
kennis / ervaring / zorg

**Olivia, 19 y.o.**

**Aberrant RCA squeezed between Ao and AP during sport = OHCA**



10

 **Angina Pectoris in the young**   
kennis / ervaring / zorg

**Anna, 13 y.o.**





Blanco history  
No risk factors

Likes to dance

Angina Pectoris during exercise

Levine's signs

11

 **Angina Pectoris in the young**   
kennis / ervaring / zorg

**Anna, 13 y.o.**





2020 Collapse in living room during dancing


No bystander CPR

ALS - eCPR protocol

Transfer UZA


Dies 2 days later

12

**Angina Pectoris in the young** 

**Anna, 13 y.o.**

**Hypertrophic cardiomyopathy causes ischemia**




**= Hereditary 1:500 !**  
Homozygous c.1828G>A or p.(Asp610Asn) exon 19 in *MYBPC3*

13

**Angina Pectoris in the young** 

**Anna, 13 y.o.**      **Sister Lena, 19 y.o.**



14

**Angina Pectoris in the young**

**Key points**


Chestpain = careful history taking

Angina in the young = serious

Cardiac investigation

ECG, imaging, exercise test, genetics

Bystander CPR is the matter of life



15

**Angina Pectoris in the young**

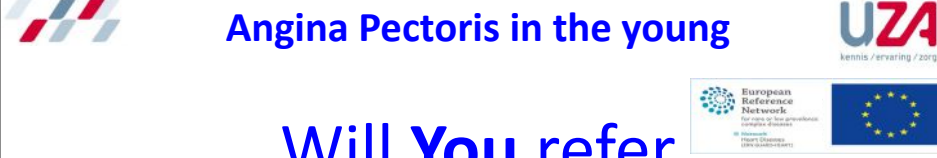
**Will You refer**

**angina pectoris in the young**



**for**

**cardiac investigation ?**



16